

Bryce Howitson

@howitson

# I DIDN'T KNOW JACK



My struggle to learn empathy for my users

#FearPersona

Bryce Howitson

@howitson

# HI, I'M BRYCE



Product Designer - Not a psychologist

#FearPersona

Bryce Howitson

@howitson

# HELPING PEOPLE CARE



Empathize with my audience  
& create engaging products

#FearPersona

*“He who knows others is wise; he who knows himself is enlightened.”*

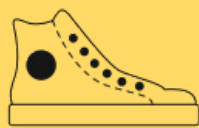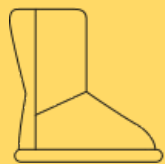**-Lao Tzu**

# KNOW THY USER

The software version

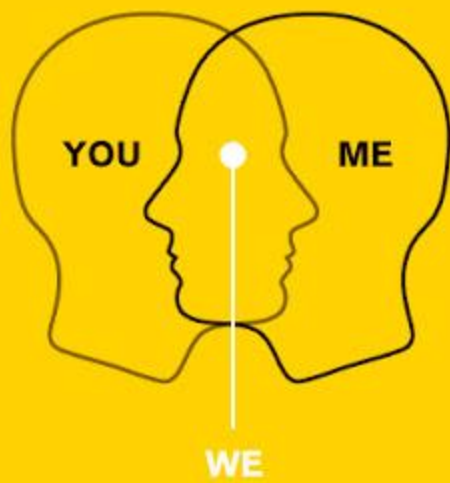
# EMPATHY

What is it & why do you care?




# Sympathy vs Compassion vs Empathy





*We were all great at empathy as kids*







# CONGRATS YOU'VE GROWN UP!

Imagination is no longer cool

**ART+DESIGN**

**NO**  
**I WILL NOT**  

---

**MAKE**  
**YOUR UGLY**  
**LOGO**  
**BIGGER.**

# TRUST ME

I'm an expert!







Meet Jack\*

\* not his real name, but it works with the story so go with it.



## Demographics:

**38 yr old surgeon,  
married, father of 2**

## Career Details

- **Harvard Med School**
- **Residency at Johns Hopkins**
- **Co-Chair, Orthopedic Surgery at  
respected sports medicine practice**



Etcetera:

- 2 years Doctors Without Borders
- Met wife in Africa (clean water NGO)
- Lives in suburban Chicago
- Drives a Tesla Model S
- Banned from hill climbs for life\*



\* Jack & Jill went up the hill...

# FIND SOME PROBLEMS

Jobs to Be Done

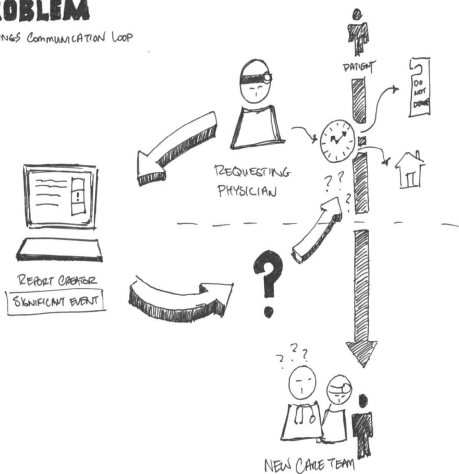
*Jack needs access to the latest medical research  
so he can up his game.*

**Jack's Job to Be Done**



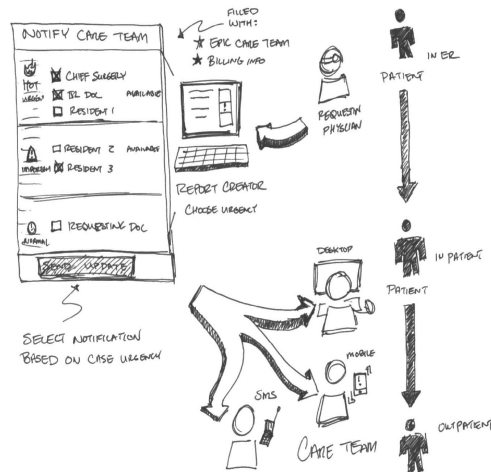
# 1 PROBLEM

Findings Communication Loop



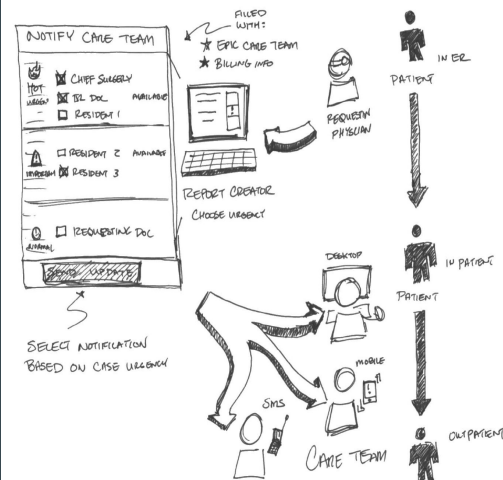
## 2. CONTACT SUGGEST

BREED IN AVAILABILITY & PATIENT CONTEXT



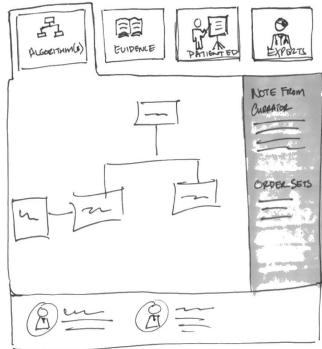
## 2. CONTACT SUGGEST

BREED IN AVAILABILITY & PATIENT CONTEXT





Info 2x 1 Best Effort



EVIDENCE

①

②

③

④

PATIENT ID

①

②

③

①

②

### SAVE TO "MY EVIDENTIA"

ITEM NAME: OPERATIONAL

PREPARE WITH ARTICLE TITLE

ORGANIZE

FOLDER NAME

SUB FOLDER

SUB SUB FOLDER

START TYPING NAME

TAG WITH KEY WORDS

LUNG @ CHEST @ LEFT @

NECK @ CAT @ BLUE @

START TYPING TO ADD TAG

SYSTEM AUTO TAGS:

ITEM TYPE

DATE PUBLISHED

JOURNAL/SOURCE

PROVIDED KEY WORDS

USER SPECIALITIES

☒ PUBLIC (ALLOW MY TEAM TO SEE & SAVE THIS)

SAVE/UPDATE CANCEL

### CRITICAL RESULTS

#### INTERNAL OVERVIEW

SHOW SECTION UPDATES

③ NEW/CHANGED

TOOL

PLAN/OPS

CONTACTS

PTED

EVIDENCE

GROUP

BACKGROUND/DEFINITION/VIDEO

NEWS/UPDATES

11/7/14 - PROCESS CHANGE

10/9/14 - BREAKING RESEARCH

TRAINING

FORMS/INTERACTIONS

ATTACH TO ONE OR OTHER EXISTING PAGES SHOULD ALSO BE PART OF ALGOS.

\* REQUIRES 2-WAY COMM THROUGHOUT NOT IN ELDAD VERSION

INTERNAL TRAINING FOR MED TEAM. WE DON'T HAVE A PLACE FOR THIS BUT COULD REPLACE PTED

MISC STUFF THAT DOESN'T FIT ELSEWHERE

MARKETING NEWS, PROCESS UPDATES NOW CONTACTS, ETC. A FEED WOULD BE NICE BUT I DOUBT IT EXISTS IN ONE PLACE SINCE ITS INTERNAL NEWS AND MARKETING/AWARENESS CONTENT

## Study report - Professional view

**Examination:**  
CT of the abdomen dated 7/21/2013.

**Comparison:**  
Radiographs same day.

**History:**  
Hiatal hernia.

**Findings:**  
The heart is not enlarged. No pericardial or pleural effusion.

C2-3: Mild posterior disc bulge without spinal canal narrowing. Bilateral uncinate and facet hypertrophy producing mild left neural foraminal narrowing. Partial fusion of the facet joints on the left likely degenerative.

C3-4: Posterior disc osteophyte complex indenting the anterior subarachnoid space and producing mild spinal canal narrowing. Bilateral uncinate and facet hypertrophy producing moderate to severe bilateral neural foraminal narrowing.

C4-5: Mild posterior disc bulge without spinal canal narrowing. Bilateral uncinate and facet hypertrophy producing mild right and moderate to severe left neural foraminal narrowing. Partial fusion of the left facet joints likely degenerative.

C5-6: Posterior disc bulge without spinal canal narrowing. Bilateral uncinate and facet hypertrophy producing moderate to severe bilateral neural foraminal narrowing.

C6-7: Minimal retrolisthesis of the anterior subarachnoid space and facet hypertrophy producing mild right and moderate to severe left neural foraminal narrowing.

C7-T1: Posterior disc bulge without spinal canal narrowing. Bilateral uncinate and facet hypertrophy producing moderate to severe bilateral neural foraminal narrowing.

**Impression:**  
1. Large paraesophageal hernia with volvulus of the stomach. (Critical Result: Volvulus) (Series 4 Image 32)  
2. Ventral abdominal wall hernia containing nonobstructed loops of small bowel.  
3. Left adrenal nodule measuring 1.4 cm. Recommend obtaining prior CT to confirm that this is an adenoma if one exists or alternatively CT adrenal mass protocol or MRI adrenal mass protocol. (Incidental Finding) (Series 2 Image 48)  
4. Severe degenerative changes of the thoracolumbar spine with severe rotoscoliosis and intact spinal rods.

### Report tags

- Radiology
- CT
- Abdomen
- neural
- adrenal



### Suggest Terms

**Meet K.E.R.I. - The Evidentia Bot**  
Knowledge Encapsulated Report Interface  
Makes content recommendations based on report context like critical results & tagging system.

## Study conversation + suggestions

**Bryce Howitson added a file:** 03/24/15 9:35 am

Ohh, its a file.pdf

Hey I just shared a file. This is my comment about it...

**Jim B-Reay said:** 03/24/15 9:43 am

Look at me I'm a text comment!

**KERI suggests:**  
Suggested topics based on study context

Adrenal Nodule      Hernia      spine

rotoscoliosis

Search Radiology Review Articles

**Critical Result**

Large paraesophageal hernia with volvulus of the stomach.

Hiatal hernia CPM Algorithm  
What's a Hernia? Patient Education  
Hiatal hernia treatment options Patient Education

**Bryce Howitson said:**

@KERI Tell me a joke

**KERI says:**

Patient to X-ray technician after swallowing some money:  
'Do you see any change in me?'

**Jim B-Reay said:**

@KERI What's a paraesophageal hernia?

**KERI found this on MeSH:**

A hiatus hernia or hiatal hernia is the protrusion (or herniation) of the upper part of the stomach into the thorax through a tear or weakness in the diaphragm. Hiatus hernias often result in heartburn but may also cause chest pain or pain with eating.

## Results: RRA or Custom Google Search

**Radiology Review Articles**  
With Radiology Search Engine

**Radiology Review Articles**  
Breast Radiology  
Articles, Signs, Websites, Conferences, Books, Journals, Societies

**Cardiac Radiology**  
Articles, Signs, Websites, Conferences, Books, Journals, Societies

localhost:2797/search/PatientEd?Term=thyroid%20nodes

Log On Home thyroid nodes

thyroid nodes FIND

EVIDENTIA

Profile

Patient Ed Evidence Google Experts Algorithms Bundles

Select content to prescribe.

Print Email

FEATURED PATIENT EDUCATION

Institutional Selections Thumbed Up by others My Bookmarks

Thyroid Nodules website Up To Date

Thyroid Nodules website Up To Date

Thyroid nodule website Medline Plus

Thyroid nodule

Thyroid nodules are solid or fluid-filled lumps that form within your thyroid, a small gland located at the base of your neck, just above your breastbone. The great majority of thyroid nodules aren't serious and ... www.mayoclinic.com

Thyroid nodules

www.nlm.nih.gov

UpToDate Mayo Clinic MedlinePlus Micromedex

PRIORITY: All Adult Pediatric INCLUDE: All

Patient information: Thyroid nodules (Beyond the Basics)

medical\_patient UpToDate

Patient information: Thyroid nodules (The Basics)

medical\_basics UpToDate

Patient information: Hyperthyroidism (overactive thyroid) (Beyond the Basics)

medical\_patient UpToDate

Feedback Get Started

This information is meant only to complement, not to replace, the information and guidance provided by your healthcare provider. It is not intended to be used as a substitute for professional medical advice, diagnosis, or treatment. No warranty is made for the accuracy, completeness, or timeliness of the information. For these reasons, this information should not be used to establish the legal standard of care in any particular situation.

localhost:2797/Home/Wrapper?Url=http%3A%2F%2Fabs.evidentiahealth.com%2Fprojects%2Falgos%2F&Provider=google&ResourceId=

Log On Home thyroid nodes View Resource - Thyroid Nodule Dy...

thyroid nodes FIND

EVIDENTIA

Profile

Bookmark Like Dislike

Does patient have a history of radiation exposure?

Yes

✓ No

Care Process Model

Thyroid Nodule

Reset

Question

Do any immediate family have a history of thyroid cancer?

If Yes:

This patient is considered high risk

✓ Yes

✓ No

1. Revised American Thyroid Association Management Guidelines for Patients with Thyroid Nodules and Differentiated Thyroid Cancer. *Thyroid* 2009;19:1167.

2. Management of Thyroid Nodules Detected at US Society of Radiologists in Ultrasound Consensus Conference Statement. *Radiology* 2009;237:794.

3. Incidental thyroid nodules detected at imaging: can diagnostic workup be reduced by Use of the Society of Radiologists in Ultrasound recommendations and the three-tiered system? *J Am Coll Radiol* 2011;18:201-11.

4. Incidental thyroid nodules detected at imaging: can diagnostic workup be reduced by Use of the Society of Radiologists in Ultrasound recommendations and the three-tiered system? *J Am Coll Radiol* 2011;18:201-11.

5. Risk of Thyroid Cancer Based on Thyroid Ultrasound Imaging Characteristics: Results of a Population-Based Study. *JAMA Intern Med* 2013; Oct 28;173(18):1788-96.







**I THOUGHT, I'D  
EMPATHIZED WITH JACK**

Hadn't I?

**I WAS TOO RIGID**





# CONFESSION



1. **Sweaty Palms**
2. **Increased Heart Beat**
3. **Mind Blank**
4. **Flight mentality**







**EYEBALLS = SOMETHING'S  
REALLY WRONG**





ONE FOR ALL & ALL  
FOR ONE

*An anxious feeling, caused by our anticipation  
of some imagined event or experience*

- Dr. Karl Albrecht

# BLAME EVOLUTION

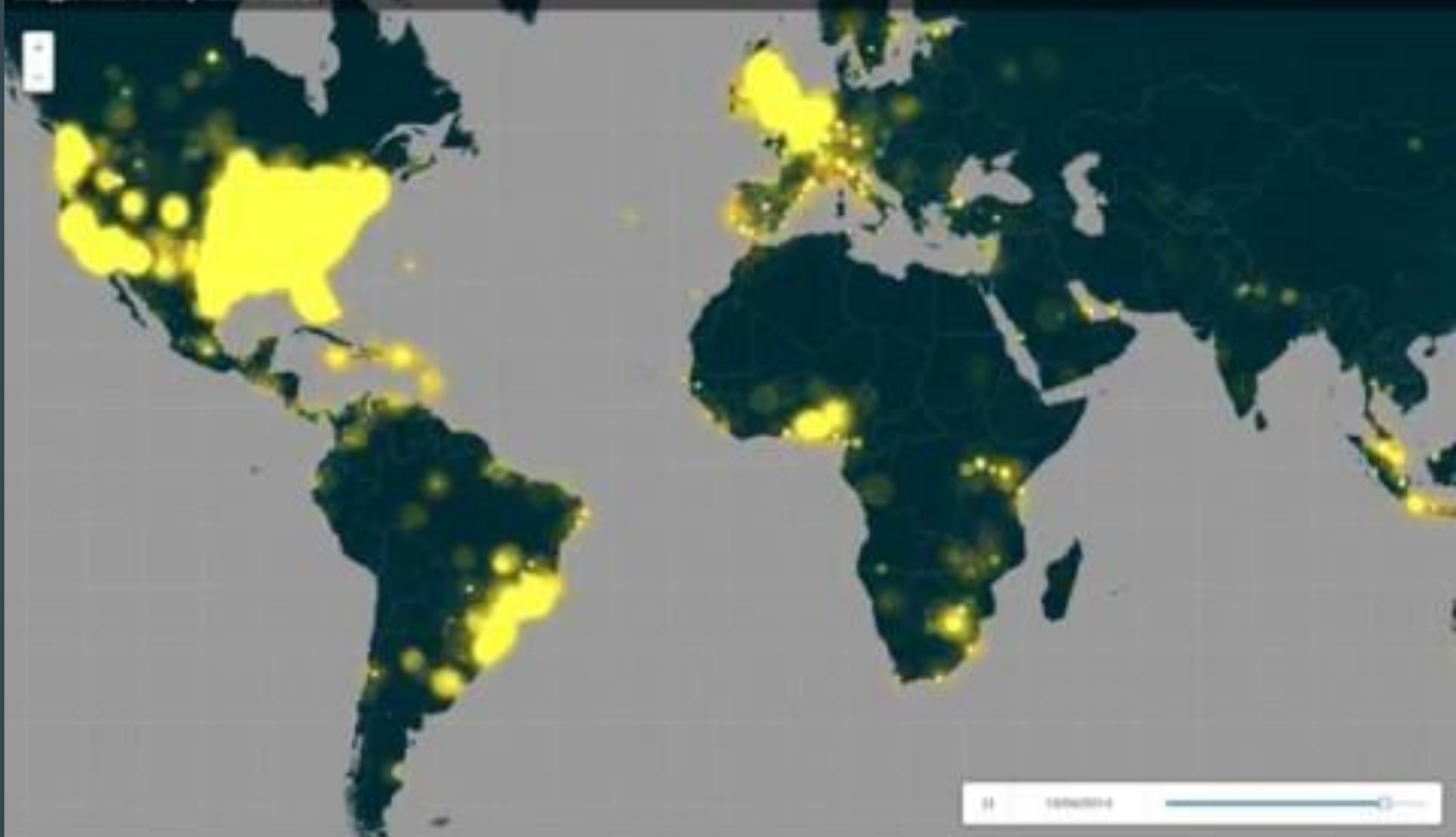But there's a good reason for this..



1. Extinction
2. Mutilation
3. Loss of Autonomy
4. Separation
5. Ego-Death



Two months in #Ebola on Twitter  
Geotagged Tweets mentioning "Ebola" or #Ebola, DMF

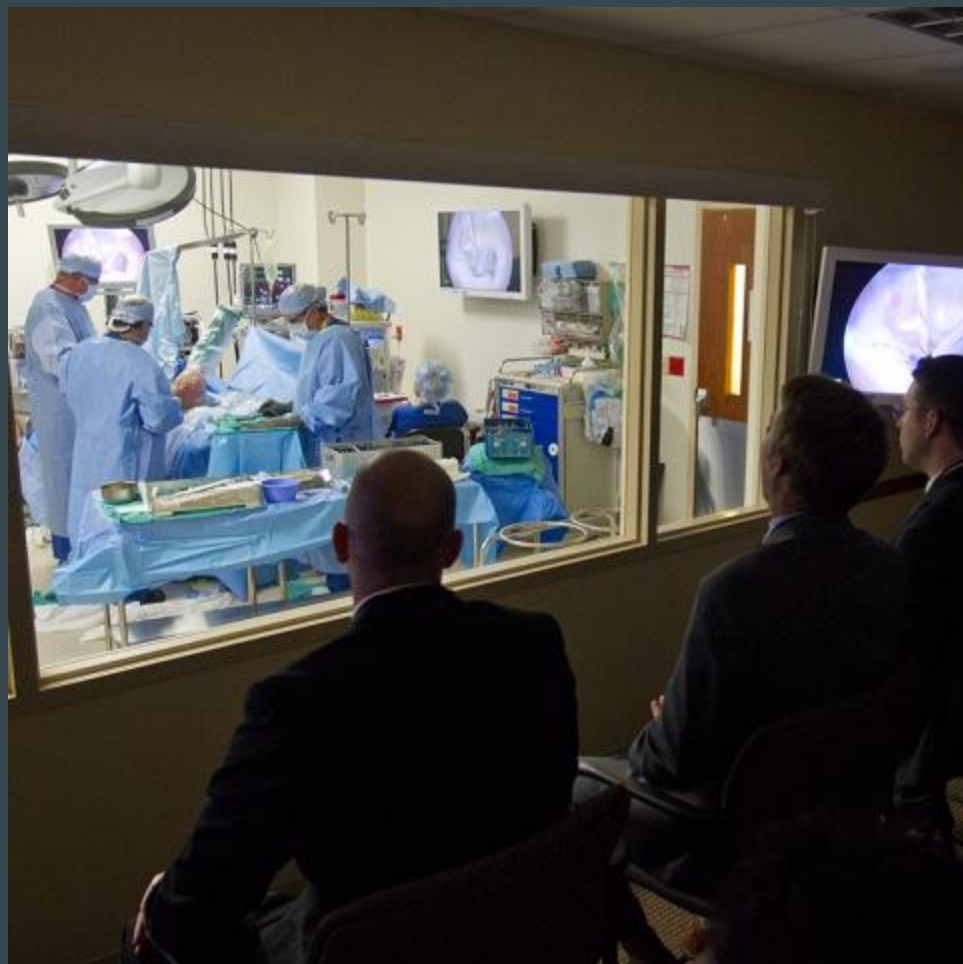







# CONNECTING WITH OUR AUDIENCES THROUGH FEAR



*Doctors are a very different type of tech user  
than anyone else you'll ever encounter.*

- My lying friends

*The real Jack*



1. But Dr. Google says...
2. Patients are walking lawsuits
3. 7 minutes ~~in heaven~~ with patients
4. I don't look good in orange jumpsuits
5. Anyone listening?

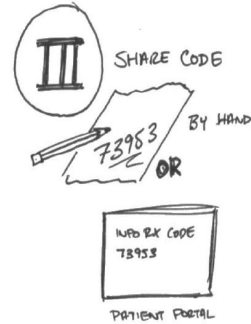
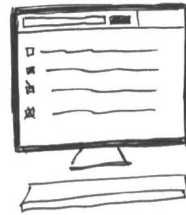
**WHAT IF MY DECISION  
KILLS SOMEONE?**



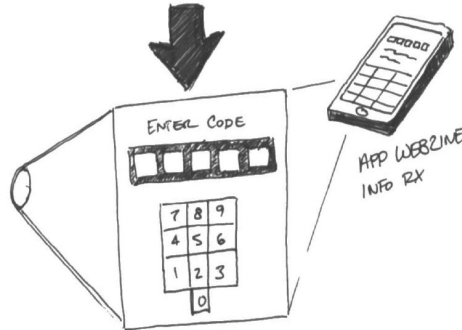




# I CARE TEAM SELECT CONTENT



WITHIN 5 DAYS



- ### BENEFITS
1. EASY TO DO
  2. SIMILAR PROCESS TO MED RX
  3. SAME CONTENT PRINTED OR ON DEVICE
  4. NO PATIENT INFO
  5. MINIMAL INTEGRATION
  6. DOCTORS DON'T SPEND TIME ON PRINTER MAINTENANCE
  7. CARE GIVER / FRIEND CAN ASSIST WITH TECH ISSUES

HOW TO SHARE INFO RX'S 4/23/14





**SHUT YO FACE**

**LEARN SOMETHING**

~~EXPERT~~  
~~EXPERT~~

# FEAR PERSONAS



1. But Dr. Google says...
2. Patients are walking lawsuits
3. 7 minutes ~~in heaven~~ with patients
4. I don't look good in orange jumpsuits
5. Anyone listening?

# HUMAN CONDITION

Bryce Howitson

@howitson

# THAT WASN'T SO SCARY



Feedback (or tips) appreciated!  
<http://bit.ly/fearpersona>

#FearPersona